



Plantar Fascia Rupture in a Professional Football Referee

Profesyonel Futbol Hakeminde Plantar Fasya Rüptürü

Gürhan Dönmez¹, Naila Babayeva¹, Ş. Şeyma Torğutalp¹, Levent Özçakar²

¹Sports Medicine Department, Faculty of Medicine, Hacettepe University, Ankara, Turkey

²Physical Therapy and Rehabilitation Department, Faculty of Medicine, Hacettepe University, Ankara, Turkey

ABSTRACT

Painful plantar heel in athletes can cause significant discomfort and limping due to difficulty in weight-bearing. Plantar fasciitis and calcaneal spurs are frequently associated with this condition. Herein, a 33-year-old male football referee with plantar fascia rupture following a local corticosteroid injection for the relief of heel pain due to calcaneal bony spur is presented. The diagnosis was confirmed through ultrasonography (USG) of the heel, and platelet-rich plasma (PRP) injection was performed under USG guidance. With a well designed rehabilitation program, he returned to his previous activity level on the 10th week of injury, without any complications. This case report is presented to highlight the potential complications of blinded corticosteroid injections amongst professional athletes, and it cautions physicians who prescribe or intervene by using.

Keywords: Plantar fasciitis, epin calcanei, ultrasonography, corticosteroids, PRP

ÖZ

Topuk ağrısı sporcularda özellikle yük binen durumlarda belirgin rahatsızlık yaratabilen bir sorundur. Buna en sık neden olan durum ise plantar fasiit ve kalkaneal spurlardır. Bu olgu sunumunda, topuk dikenini nedeniyle lokal kortikosteroid enjeksiyonunu takiben gelişen plantar fasya rüptürü olan 33 yaşında profesyonel bir futbol hakemi sunulmaktadır. Hastanın tanısı konulduktan sonra ultrason kılavuzluğunda trombositten zengin plazma (TZP) enjeksiyonu yapıldı, rehabilitasyon sürecinin ardından hasta 10 hafta sonra herhangi bir şikayeti olmadan eski aktivite düzeyine döndü. Bu olgu sunumunun amacı körlemesine yapılan kortikosteroid enjeksiyonlarının profesyonel sporcularda yaratabileceği ciddi komplikasyonlara dikkat çekmektir.

Anahtar Sözcükler: Plantar fasiit, epin kalkanei, ultrason, kortikosteroid, PRP

Available at: <http://journalofsportsmedicine.org> and <http://dx.doi.org/10.5152/tjism.2018.094>


Cite this article as: Donmez G, Babayeva N, Torgutalp SS, et al. Plantar fascia rupture in a professional football referee. *Turk J Sports Med.* Published Online: 26th April, 2018.

INTRODUCTION

Painful heel spur syndrome is a common disease with a lifetime prevalence of approximately 10% (1). The pathogenesis of this syndrome is multifactorial, including plantar fasciitis, increased intra-osseous pressure of the os calcis, calcaneal periostitis and presence of calcaneal spur (2). Plantar fasciitis is the most commonly reported cause of chronic pain beneath the heel, and is very frequent especially among athletes whose activities include large amounts of running and jumping. This condition

G. Dönmez 
0000-0001-6379-669X

N. Babayeva 
0000-0002-2695-0456

Ş.Ş. Torğutalp 
0000-0003-4488-8470

L. Özçakar 
0000-0002-2713-4071

Geliş Tarihi / Date Received:
23.11.2017

Kabul Tarihi / Date Accepted:
21.02.2018

Yayın Tarihi / Published Online:
26.04.2018

Yazışma Adresi /

Corresponding Author:

Gürhan Dönmez

Hacettepe Üniversitesi, Tıp

Fakültesi, Spor Hekimliği

Anabilim Dalı, Ankara,

Turkey

E-mail:

gurhan.donmez@hacettepe.edu.tr

©2018 Türkiye Spor Hekimleri
Derneği. Tüm hakları saklıdır.

quite often appears with the concomitant presence of a plantar calcaneal heel spur (3). Plantar calcaneal enthesophyte (heel spur) is a bony outgrowth or calcification along the medial tuberosity. An inferior calcaneal spur is usually located on the inferior aspect of the calcaneus and is typically a response to plantar fasciitis over a period. Plantar fascia ruptures typically occur during high impact activities and have recently been reported in the setting of preexisting plantar fasciitis, and rarely occur spontaneously (4). Furthermore, individuals with abnormal gait, structural abnormalities, improper footwear, or who are overweight are all more likely to rupture their plantar fascia than others. It is often associated with long-standing flat feet deformity.

Herein, a case of acute plantar fascia rupture in a professional football referee who received a local injection of corticosteroid (triamcinolone) in his medical history for the treatment of calcaneal spur is presented. The possible reason of plantar fascia rupture was thought to be due to blinded corticosteroid injection. The main objective to present this case is to remind higher risk for plantar fascia rupture following steroid injections for plantar fasciitis and to highlight safer PRP injections under ultrasonography guidance.

CASE REPORT

A 33-year-old male football referee applied to the sports medicine clinic with complaints of severe pain in the plantar side of the right foot and limping for one week. He described a popping after an acceleration type of motion in his sole during a professional football match, almost at the end of the first half. Although, a sudden tearing episode in the heel was felt by the referee, he resumed to administrating the game until the last whistle. Clinical investigation revealed edema at the plantar side of the foot, very painful with palpation. He was examined in another private clinic through magnetic resonance imaging of the foot and was diagnosed with partial rupture of the plantar fascia (Figure 1). He was advised to use nonsteroidal antiinflammatory medication and insoles for initial treatment with partial weight-bearing. After a detailed medical history, the patient also reported a local corticosteroid injection for the relief of heel pain due to calcaneal bony spur about two months ago and had kept on physical activity few days after the injection (Figure 2). His medical history was otherwise noncontributory.

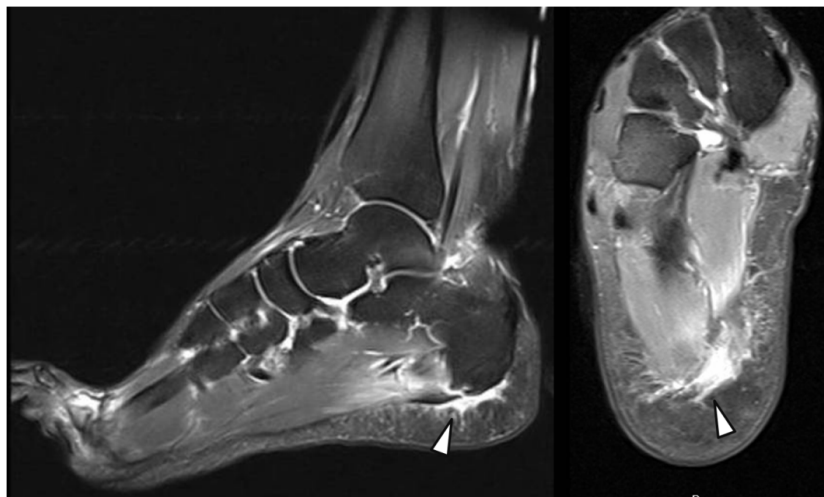


Figure 1. Magnetic resonance imaging reveals partial interruption of the normally low-signal-intensity fascia (arrow) on a sagittal T2 weighted fat saturated image (A), axial high resolution T2 weighted image (B)

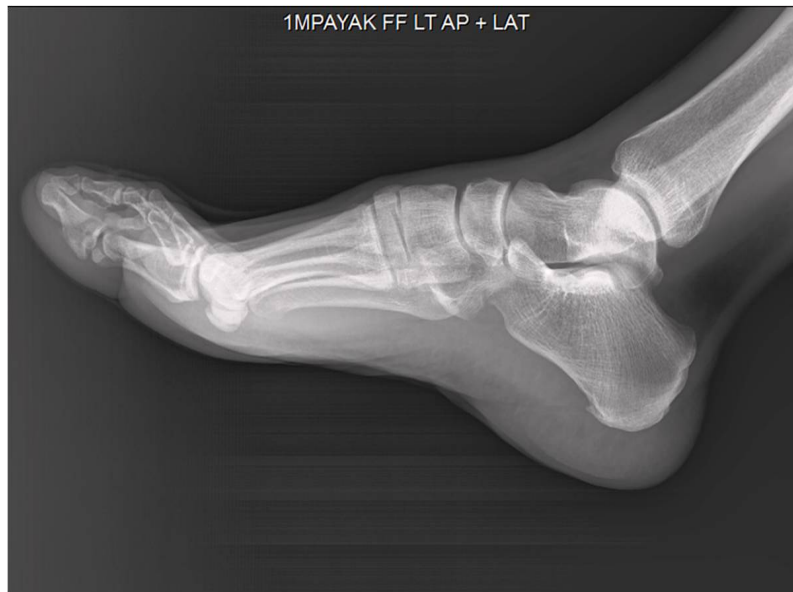

Figure 2. Direct radiograph showing heel spur situated at the plantar part of the calcaneus

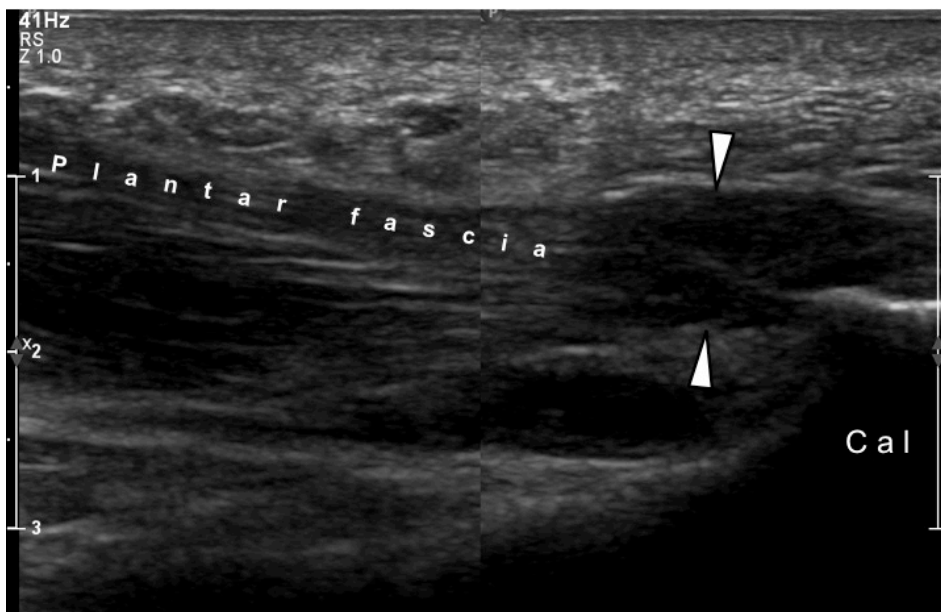


Figure 3. Ultrasonography (long axis, split screen view) demonstrating edema and increased thickness (arrowheads) of the plantar fascia at its calcaneal (Cal) attachment site

Ultrasonography (USG) of the heel revealed swollen plantar fascia and a single dose of platelet-rich plasma (PRP) injection (BCT, Regenlab, Le Mont-sur-Lausanne, Switzerland) was performed under USG guidance (Figure 3).

He was advised to use arch supports, ice packs and short-term activity modification with limited weight-bearing. Then, a rehabilitation program including stretching exercises combined with strengthening of the ankle was

immediately started. He was advised not to do high-impact activities and to do stretching exercises for the first four weeks. Running activities were allowed six weeks after the injury. He returned to his previous activity level on the 10th week of injury without any complications. He was appointed as the first referee in the following week in the elite division, and no recurrence was reported after two years of follow-up.

DISCUSSION

Painful plantar heel is a relatively common clinical entity in athletes and active people, and it can cause significant discomfort and limping because of the difficulty in weight-bearing. Plantar fasciitis and calcaneal spurs are frequently associated with this condition. Plantar calcaneal spurs were originally considered as the cause of plantar fasciitis, but it is now regarded that plantar calcaneal spur may be an indicator of foot pain independent of plantar fasciitis as well. It is usually caused by a biomechanical imbalance resulting in tension along the plantar fascia. Obesity, older age, abnormal pronation, reduced ankle dorsiflexion, tight Achilles tendon, inadequate or inappropriate footwear, excessive running and prolonged standing were shown to be associated risk factors for developing plantar fasciitis or calcaneal spur (4).

Since the diagnosis is primarily based on clinical findings, thorough history and careful physical examination are necessary for the appropriate management. Conservative management consisting of rest, activity modification, ice massage, anti-inflammatory medications, stretching techniques, physical therapy modalities, extracorporeal shock wave therapy and insole supports can be tried in the initial treatment. Most clinicians prefer corticosteroid and local anesthetic injections into the calcaneal origin of the plantar fascia to relieve pain, and promote healing if heel pain persists (5).

Steroid injections are often used to decrease pain and inflammation in the short term. However, they have been shown to cause fat pad

atrophy and, very occasionally, they may precipitate rupture of the plantar fascia (6,7). Ruptures are usually seen at the medial portion. Kim et al. performed a retrospective review of 120 patients who received corticosteroid injection for plantar fasciitis (7). They reported four patients (2.4%) who suffered plantar fascia rupture following corticosteroid injections. Although they reported that corticosteroid injection therapy was safe and effective with minimal complications (and a relatively low incidence of plantar fascia rupture); higher rates of plantar fascia rupture after corticosteroid injections were also reported (8). On the other hand, Acevedo published one of the largest patient series for plantar fascia rupture and reported that 44 of 51 patients were associated with corticosteroid injections (6). About 68% of those patients reported a sudden onset of tearing at the heel. The risk of rupture is reduced if the injection is performed on the medial side of the heel, superior to the plantar fascia. Limited number of cases for professional athletes having plantar fascia rupture after corticosteroid injection were reported in the literature (9).

Under the light of literature, it was speculated that the possible reason of plantar fascia rupture in our case was former corticosteroid injection. Despite US-guided corticosteroid injections were shown to be safe and effective in the short-term therapeutic outcome of chronic plantar fasciitis, injection of corticosteroid deep to the fascia might result in greater reduction in plantar fascia thickness, pain and disability, and improved foot-related quality of life (10). The blinded injection in our patient can be speculated as to be performed superficial to the plantar fascia.

Among the various lesions of the hindfoot in athletes, plantar fascia ruptures are not well documented, and a treatment protocol is not often reported in the literature. Treatment of plantar fascia rupture consists of immobilization with a nonweight-bearing short-leg cast or a removable boot cast for at least three weeks, and a regimen of antiinflammatory therapy. Saxena reported complete return to activity in a

mean time of 9.1 weeks for all patients without any reinjury, postinjury sequelae nor surgery (11). After failure of a well conducted conservative treatment, surgical treatment of plantar fascia rupture must be proposed. PRP should be considered as another option for the treatment with its autologous, anti-infective feature and low side effect rates. PRP preparations contain high concentrations of platelets that, once activated, undergo degranulation to release growth factors with healing properties (12).

Due to its autogenous origin, easy preparation, inexpensive and excellent safety profile, the use of PRP technology has been increasingly used in sports-related injuries for therapeutic applications (13). Popularity of PRP in other applications in orthopaedic sports medicine increased recently as it accelerates physiologic healing and earlier return to activity. Evidence-based biological and clinical outcomes of PRP are still controversial despite the promising effects of its common usage. Despite the lack of hard evidence through randomized clinical trials, clinical observation and opinion suggest that pain relief and return to function occur more rapidly than expected for some healing orthopaedic problems after the use of PRP (14). Since sports medicine patients desire earlier return to training and competition, PRP may provide certain applications that will speed recovery in cases of tendon, ligament, muscle and cartilage disorders. USG-guided injections enable real-time imaging of the plantar fascia during needle insertion (5). It was shown that USG-guided injections provide greater pain relief in plantar fasciitis, and lower recurrence of heel pain compared with palpation-guided injections (15). Therefore, it is indisputable that USG-guided PRP injection is more effective to accelerate healing process than blinded injections (16).

CONCLUSION

In conclusion, it should be noted that plantar fascia ruptures have recently been reported in the setting of pre-existing plantar fasciitis as the main risk factor of associated injections rather

than being acute injuries. Therefore, this case report highlights that blinded steroid injections for plantar fasciitis should be cautiously administered because of the higher incidence of plantar fascia rupture due to risk of long-term sequelae that are difficult to resolve. Moreover, clinicians should be aware that USG-guided injections are safer than blind injections.

REFERENCES

- Hautmann MG, Neumaier U, Kölbl O. Re-irradiation for painful heel spur syndrome. Retrospective analysis of 101 heels. *Strahlenther Onkol.* 2014; 90(3):298-303.
- Zhou B, Zhou Y, Tao X, et al. Classification of calcaneal spurs and their relationship with plantar fasciitis. *J Foot Ankle Surg.* 2015; 54(4):594-600.
- Salvi AE. Targeting the plantar fascia for corticosteroid injection. *J Foot Ankle Surg.* 2015;54(4):683-5.
- Lee HS, Choi YR, Kim SW, et al. Risk factors affecting chronic rupture of the plantar fascia. *Foot Ankle Int.* 2014;35(3):258-63.
- Kayhan A, Gökay NS, Alpaslan R, et al. Sonographically guided corticosteroid injection for treatment of plantar fasciosis. *J Ultrasound Med.* 2011;30(4):509-15.
- Acevedo JI, Beskin JL. Complications of plantar fascia rupture associated with corticosteroid injection. *Foot Ankle Int.* 1998;19(2):91-7.
- Kim C, Cashdollar MR, Mendicino RW, et al. Incidence of plantar fascia ruptures following corticosteroid injection. *Foot Ankle Spec.* 2010;3(6):335-7.
- Leach R, Jones R, Silva T. Rupture of the plantar fascia in athletes. *J Bone Joint Surg Am.* 1978;60(4):537-9.
- Suzue N, Iwame T, Kato K, et al. Plantar fascia rupture in a professional soccer player. *J Med Invest.* 2014;61(3-4):413-6.
- Gurcay E, Kara M, Karaahmet OZ, et al. Shall we inject superficial or deep to the plantar fascia? An ultrasound study of the treatment of chronic plantar fasciitis. *J Foot Ankle Surg.* 2017;56(4):783-7.
- Saxena A, Fullem B. Plantar fascia ruptures in athletes. *Am J Sports Med.* 2004;32(3):662-5.
- Boswell SG, Cole BJ, Sundman EA, et al. Platelet-rich plasma: a milieu of bioactive factors. *Arthroscopy.* 2012; 28(3):429-39.
- Taylor DW, Petrera M, Hendry M, et al. A systematic review of the use of platelet-rich plasma in sports medicine as a new treatment for tendon and ligament injuries. *Clin J Sport Med.* 2011; 21(4):344-52.
- Utku B, Dönmez G, Büyükođan K, et al. Platelet-rich plasma: from laboratory to the clinic. In: Doral MN, Karlsson J, editors. *Sports Injuries: Prevention, Diagnosis, Treatment and Rehabilitation.* 2nd ed. Heidelberg: Springer-Verlag Berlin; 2015. p. 3223-50.

15. Li Z, Xia C, Yu A, et al. Ultrasound-versus palpation-guided injection of corticosteroid for plantar fasciitis: a meta-analysis. *PLoS One*. 2014;9(3):e92671.
16. Tsai WC, Hsu CC, Chen CP, et al. Plantar fasciitis treated with local steroid injection: comparison between sonographic and palpation guidance. *Clin Ultrasound*. 2006;34(1):12-6.